

4° EXPERT MEETING GREENLIGHT LASER
Padova, 18 Aprile 2018

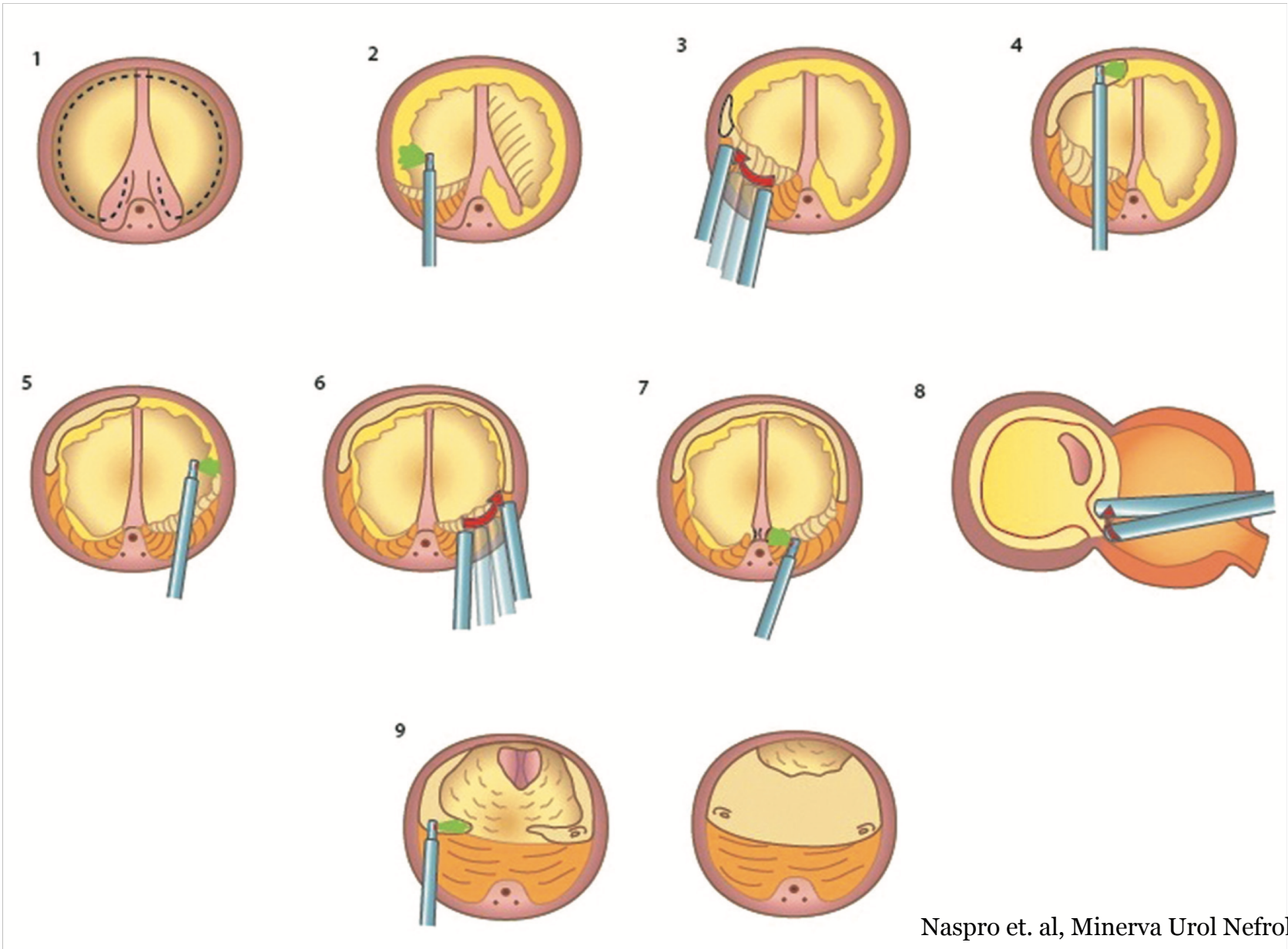
Il trattamento Green visto (e ri-visto) dai giovani urologi: quali modifiche nella tecnica e perché?

Francesco Varvello *MD, FEBU, FECSM*



S.C. Urologia
P.O. San Lazzaro ASL CN 2
Alba

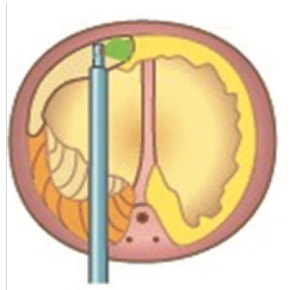
GreenLEP technique



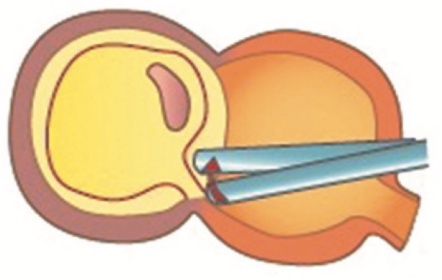
GreenLEP en-bloc: quali difficoltà?



ORIENTAMENTO



SVILUPPO DEL PIANO ANTERIORE




ADENOMI VOLUMINOSI

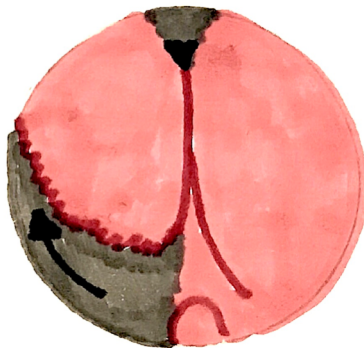
GreenLEP en-bloc modificata



Vaporizzazione della commissura anteriore




Demarcazione apicale lobo destro

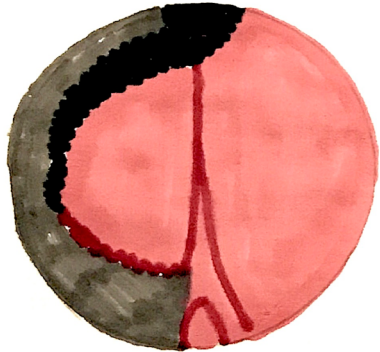

Scollamento postero-laterale lobo destro


GreenLEP en-bloc modificata



Si raggiunge il lume vescicale a ore 10

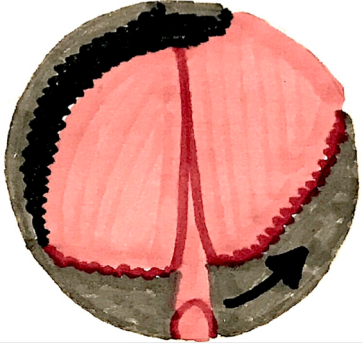


Sezione anteriore del collo vescicale fino a raggiungere la commissura e scollamento anteriore del lobo fino all'apice




Demarcazione apicale lobo sinistro

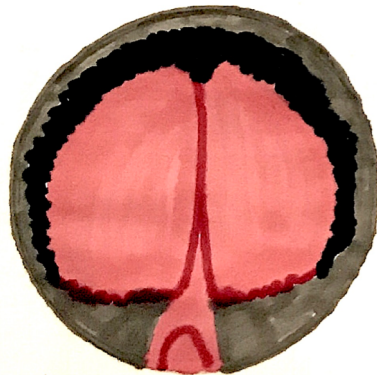
GreenLEP en-bloc modificata



Scollamento postero-laterale lobo sinistro




Si raggiunge il lume vescicale a ore 2




Sezione anteriore del collo vescicale fino a raggiungere la commissura e scollamento anteriore del lobo fino all'apice


GreenLEP en-bloc modificata



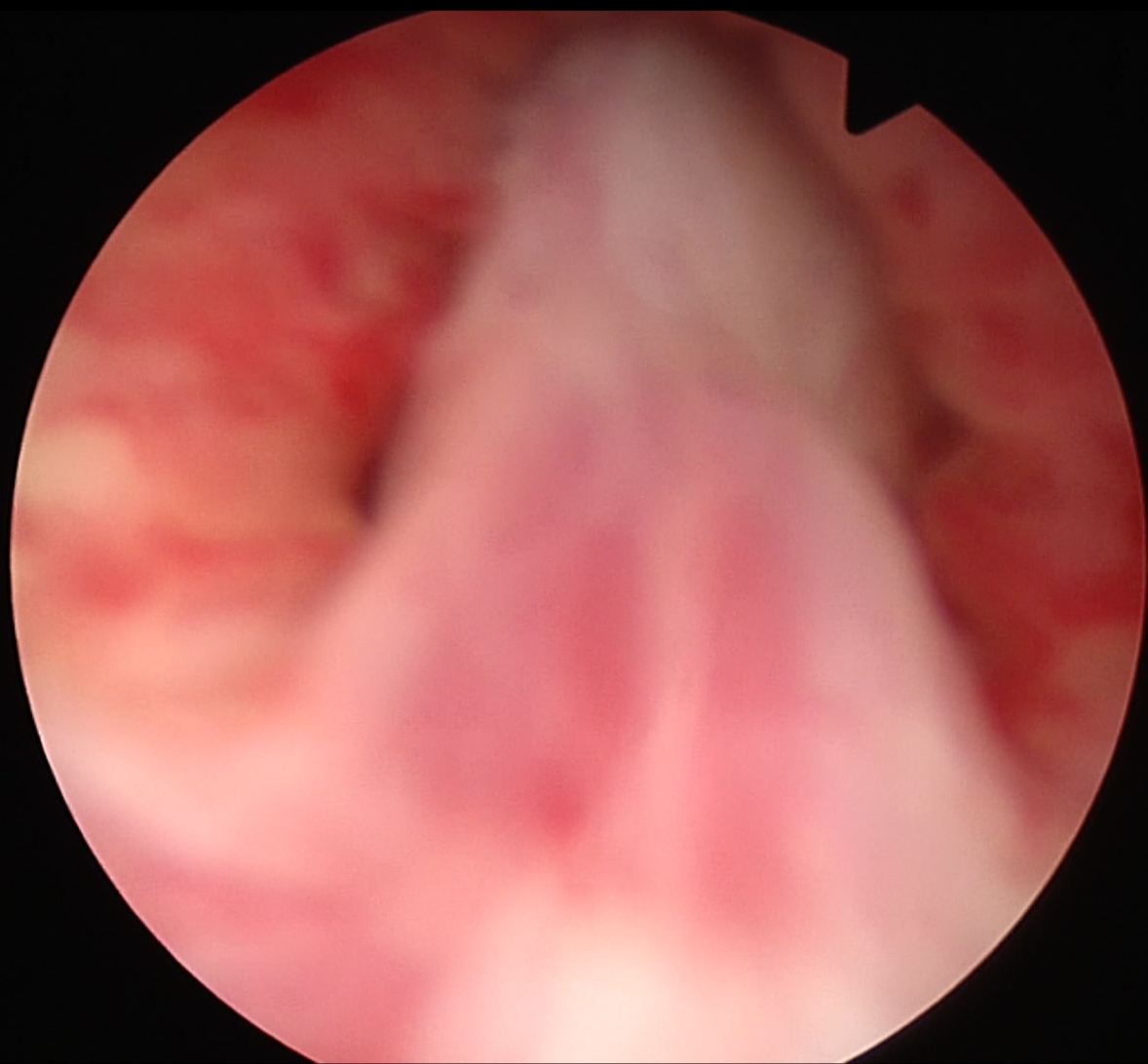
Sezione della cresta uretralis



Scollamento posteriore dei lobi



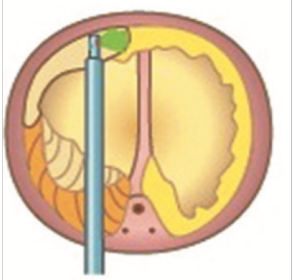
Ribaltamento dell'adenoma in vescica e sezione posteriore del collo vescicale



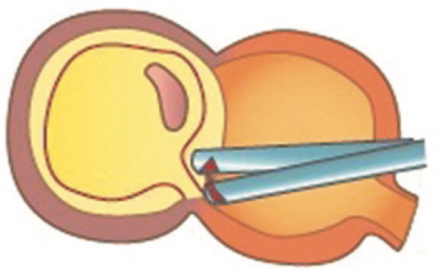
GreenLEP en-bloc modificata



SISTEMATICA, OFFRE PUNTI DI RIFERIMENTO AGGIUNTIVI



FACILITA LO SVILUPPO DEL PIANO ANTERIORE



POSSIBILITA' DI DIVIDERE IN DUE BLOCCHI SE ADENOMI VOLUMINOSI